

## A REVIEW OF FATAL AND NEAR FATAL FOREIGN BODY IN THE PAEDIATRIC AIRWAY: TIMELY INTERVENTION COUNTS.

<sup>1,4</sup>Omokanye, H. K., <sup>2,4</sup>Adegboye, K.A., <sup>3,4</sup>Nasir A. A., <sup>2</sup>Adegboye, M. B., <sup>1</sup>Afolabi O.A., <sup>5</sup>Patric E.W., <sup>5</sup>Thimnu Ari Elam W., <sup>6</sup>Isa A., <sup>1</sup>Segun-Busari, S., <sup>1</sup>Dunmade A.D.

Departments of <sup>1</sup>Otorhinolaryngology, <sup>2</sup>Anaesthesiology, <sup>3</sup>Paediatrics Surgery, University of Ilorin Teaching Hospital/University of Ilorin, Ilorin, Nigeria, Departments of <sup>5</sup>Nursing, <sup>6</sup>Ear Nose and Throat, Federal Medical Centre. Yola, Adamawa, Nigeria.

<sup>4</sup>Crescent Gold Crown Hospital, Oluwafunmilayo-Agboola Street. Off University Road, Ilorin,

### ABSTRACT

**Background:** Accidental ingestion or aspiration of foreign bodies carries a potential risk of fatality in children and early intervention is vital. The urgency often dictates prompt referral to otolaryngologist. However, at the referral center, time may not always permit the most skilled specialist to arrive the point of care. Hence, the life-saving task may fall on any other doctor or ENT trained-nurse available in the emergency room at the time of patient's arrival.

**Objective:** We analyzed contributory factors to morbidity and mortality in four selected cases; two near-fatal foreign bodies in infants, along with two others, were delayed or no intervention led to a fatal outcome.

**Method:** In the current study, a retrospective review of case files of four patients with foreign body aspiration was conducted.

**Result:** Two out of the 4 (50%) airway foreign bodies were successfully removed, one with and the other without anesthesia. One of the lifesaving foreign body retrievals was done by an ENT-trained nurse using available instruments, and the other by an anaesthetist. The other two died either because of delayed presentation or refusal to consent to surgical intervention.

**Conclusion:** The findings revealed that prompt imaging and referral to a specialist center for early intervention are important factors in the outcome. However, absence of the most skilled manpower or the best instrument should not be allowed to preclude timely intervention.

**Keywords:** Infants, foreign body aspiration, fatal outcome, consent, referral

### INTRODUCTION

Accidental ingestion or aspiration of foreign bodies (FBs) carries a potential risk of fatality in children and early intervention is vital. Commonly aspirated FB varies from countries to countries according to the immediate play environment of the child and the mechanisms leading to potentially lethal consequences also vary with the anatomical site of impaction of the FB.<sup>1,2</sup> In any case, early diagnosis and prompt retrieval is of essence to prevent mortality. In our setting, mortalities reported from FB in the aerodigestive airway is just a tip of the iceberg, as many children do not make it to the specialist hospital which is often located in the city, miles away from the rural dwellers. This review reiterates how high index of suspicion, prompt investigation and speedy intervention could make a difference between life and death.

#### Correspondence:

Omokanye H.K.

Department of Otorhinolaryngology.

Faculty of Clinical Sciences,

College of Health Sciences, University of Ilorin.

PMB 1515, Ilorin-240003, Nigeria

Email: [omokanye.hk@unilorin.edu.ng](mailto:omokanye.hk@unilorin.edu.ng).

Tel: +2348035012930

#### Case report

##### Case-1

A nine-month-old infant of a Fulani nomad, presented in severe respiratory distress following a suspected aspiration of FB. He was playing with pebbles few meters away from his mother who was busy cooking when she suddenly noticed the child choking. After about an hour of worsening respiratory distress and failed attempts at removal by mother probing the mouth with fingers; child was taken to the nearest cottage hospital located one hour drive away. From there, child was immediately referred to a specialist hospital and subsequently to our emergency unit where they finally arrived late in the evening, well over 6 hours after. By that time, child was already weak with gasping respiration and cyanosis. A quick examination of oral cavity and oropharynx revealed mucosa bruises and bleeds; no sight of FB. Although, all

hope seemed lost; an emergency X-ray soft tissue neck done revealed the FB in the hypopharynx. No further time was wasted; the ENT-trained nurse on call quickly extended the child's neck, grabbed available instrument (tongue depressor and Tilley's forceps) depressed the tongue and inserted the Tilley's forceps in the direction of the epiglottis, the craggy feel of a stonewas felt. The instrument was then manipulated to pull up the FB to view. Thereafter it was grabbed and removed. The weak and cyanosed infant was then resuscitated with oxygen via facemask, and rehydration. Analgesics and antibiotics were also administered. Nasogastric (NG) tube was passed to stent the pharynx. Child recovered satisfactorily well.

##### Case-2

A 2-year-old girl was found within the house in respiratory distress. Mother suspected child to have ingested a FB. At presentation, child was irritable and restless with poor cry. She was in moderate respiratory distress, no cyanosis. X-ray soft tissue neck revealed a FB overhanging the glottis. Child was rushed into the emergency theatre, intravenous access secured and inducted with inhalational agent (sevoflurane).

With the neck extended once a deep plain of anaesthesia attained, laryngoscopy performed with a Macintosh laryngoscope to visualize the larynx. The FB was sighted over the glottic space then a McGill forceps was inserted to grasp and gently retrieve the foreign body.

##### Case-3

A 2-year-old girl suspected to have ingested a FB was referred from a peripheral hospital after having visited several other hospitals in the neighbouring rural town where neither imaging nor any attempt at removal was made. On getting to the tertiary health institution however, the child could not access emergency care because of an ongoing industrial strike at the time. By that time, child was hypoxic and deteriorating. He was subsequently referred to a private hospital where she had some resuscitation by oxygen administration with minimal improvement in sensorium. Attempt was made to inspect the airway with a Macintosh laryngoscope but no FB could

be visualized. Child later had cardiac arrest before the ENT surgeon arrived.

#### Case-4

A 4-year-old girl who was brought into our afternoon clinic on account of accidental FB ingestion in school. Child was said to be apparently well until 4 hours prior to presentation when the parent was alerted that the child had swallowed a piece of eraser in school. Parent met the child restless with labored breathing however, symptom spontaneously got improved in transit to the hospital. Examination revealed active child not in obvious respiratory distress, not pale anicteric. Vesicular breath sound was picked on chest auscultation. No added sound. Urgent chest X-ray was ordered and the parent was counselled for admission of the child in the hospital for close observation. However, since the child was no longer in respiratory distress parent chose (against medical advice) to take some more time to go home and prepare for hospital admission. The following day child was dead before arrival at the hospital.

#### DISCUSSION

Most incidents of FB aspiration in children are not witnessed by adults.<sup>2</sup> Attention is usually called to the child by accompanying symptoms of cough, choking and difficulty in breathing.<sup>3</sup> However, FB aspiration may be asymptomatic.<sup>4</sup> At times, the usual early symptoms may be transient and missed by unsuspecting parent or care giver.<sup>2</sup> Case 4 had no symptom at presentation and that may be the reason while the parent did not consent to admission of the child for observation and definitive management. Mu et al. found parental negligence (50%) as the leading cause of late diagnosis and complications in FB aspiration in children and the incidence of major complication was more in children with a delay in diagnosis.<sup>5</sup> Cause of delay in case-1 was distance from the nearest tertiary hospital and delay due to serial referrals to wrong centers that lack the manpower and facilities to handle the case. Precious time was wasted before the final referral to our facilities more than 12 hours later. Case-3 also lives miles away, yet was referred to our tertiary health institution within a reasonable time. But he could not access specialist care because of ongoing industrial strike by the health workers as at the time. Several hours was wasted looking for an alternative hospital where patient could access care. The child's condition had deteriorated before he could get attention at a private hospital.

Case-4 was appropriately referred from a neighboring town at a reasonable time but parent refused to give consent for treatment out of the initial confusion caused by the sudden disappearance of symptoms; perhaps they were in doubt about the presence of FB or dread surgical intervention. Unfortunately, the child died at home 24 hrs later. Our experiences in case 3 and 4 corroborate earlier findings of FB aspiration in childhood as one of the most important causes of accidental deaths.<sup>1,6,7</sup> Only case-2 presented to the hospital within the first hour of aspiration. It was by coincidence that specialist services exist at the first point of call which was the private hospital the family routinely attend. Imaging was done without undue delay and both the anesthesiologist and otolaryngologist were available within minutes.

The size, organic nature, type, and location of the FB dictate the clinical presentation of aspirated FB. Children have narrow airways; hence a big FB can get lodged in and obstruct the proximal airways (Fig. 1&2). On the other hand, a small FB may descend distally to get impacted in the right bronchial tree because of its straighter alignment with trachea compared to the left bronchus.<sup>8</sup> Organic FBs has the ability to elicit inflammatory reaction within the trachea-bronchial tissue or absorb moisture that often result in airway obstruction hours after an initially asymptomatic FB-aspiration.<sup>1,4</sup> In addition, the orientation

of the FB in the laryngotracheal lumen determines the severity of obstruction, risk of asphyxia and death. A small in-organic FB like coin may get impacted in the laryngotracheal airway, standing vertically without any feature of obstruction; the same FB at the same location may fall transversely, causing a sudden total occlusion of the airway, asphyxiation, and death. These possibilities explain the possible cause of death in case-4 who was initially asymptomatic, only to be brought-in-dead 24 hours later.

Complete foreign body airway obstruction is a medical emergency that requires immediate action like back blows or sub-diaphragmatic abdominal thrusts (Heimlich maneuver) to restore the victim's airway.<sup>7</sup> None of the cases had any correct choking first-aid from parents or care givers at home, even though all the parents were able to recognize a child in acute airway obstruction.

Otolaryngologists are relatively few in Nigeria, many tertiary health centers are being manned by ENT trained nurses while otolaryngologist are available only on locum or visiting arrangement. The life-saving FB removal in case-1 was done by an experienced ENT-nurse using available instrument (Tilley's forceps and metallic tongue depressor) in the clinic tray. As there was no luxury of time to get to the theatre for formal laryngoscopy procedure or await the presence of otolaryngologist. The importance of imaging in diagnosis and management of FB aspiration cannot be over emphasized.<sup>4</sup> Even when the clinician is in doubt of FB aspiration after a thorough physical examination, imaging should be ordered. X-ray aided the prompt diagnosis and localization of the FB in case 1 and 2. It also boosted the health worker's certainty and confidence to take the lifesaving intervention. X-ray was not ordered by the referring health worker in case-3 and 4 and it was too late to be accomplished by the time patient got to the specialist center. The best time to order for urgent X-ray soft tissue neck and chest X-ray is when the child is stable.<sup>4</sup> Therefore, as a rule every child with a suspicion of FB-aspiration must have scout X-ray of the neck and chest done. The initial diagnostic evaluation of patients with suspected FB aspiration includes obtaining a postero-anterior and lateral chest radiograph,<sup>4</sup> in addition to plain X-ray soft tissue neck- postero-anterior and lateral view. Although the visibility of the aspirated FB depends on its radio-opacity, size, anatomical position in the airway and the imaging modality used. The aspirated FB in case 1 and 2 were stone and metallic cuff link respectively (Fig. 1 and 2). They were both inorganic and radio-opaque unlike organic FBs like food particles or toys that are generally radiolucent and may not be visible. Case 4 was suspected to have aspirated an eraser in school while the nature of FB aspirated by case 3 was unknown. Neither of them had imaging done and the location and nature of the FB could not be ascertained. Although, indirect signs of FB aspiration on plain radiograph of soft tissue neck and chest may include; air trapping sign, mediastinal shift, hyperlucency of the lung fields, atelectasis, consolidation etc., absence of these signs does not exclude FB aspiration.<sup>4</sup> Computed tomography (CT) of chest helps in localizing and evaluating radiolucent FB and provides better information compared to a plain radiograph.<sup>4,9</sup> Before now, the use of CT-scan as the first line in the diagnosis of airway FB in children has probably been limited due to the attributed high radiation dose. Recent technological advancement has produced Ultralow-dose CT of the airways which uses radiation dose protocol equivalent to conventional radiographic methods and maintains the high sensitivity and specificity for detection of FBs.<sup>9</sup> In our setting, CT-scan is not as readily available as X-ray which is cheap, affordable, and readily accessible to patients. CT-scan was not available in any of the health centers attended by case 1-4.

Cricothyroidotomy or emergency tracheostomy may be indicated to save life in children with imminent airway obstruction from suspected large FB in the upper airway

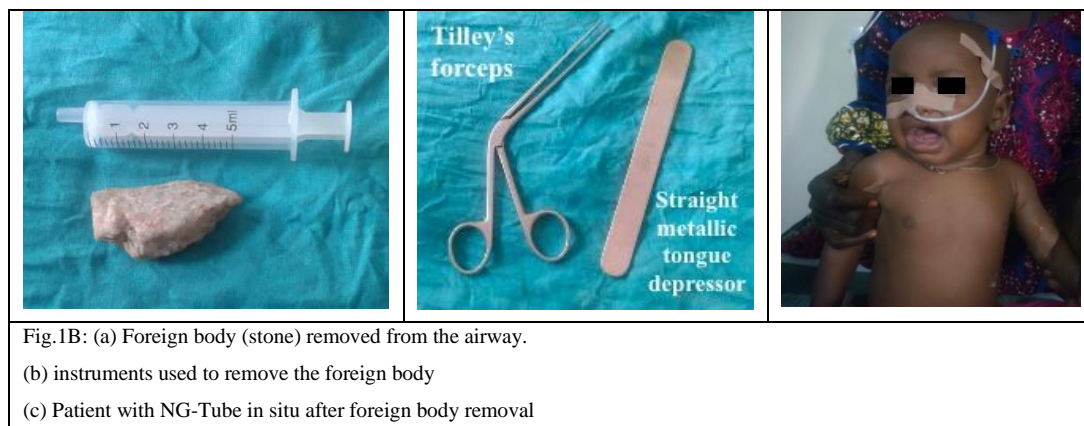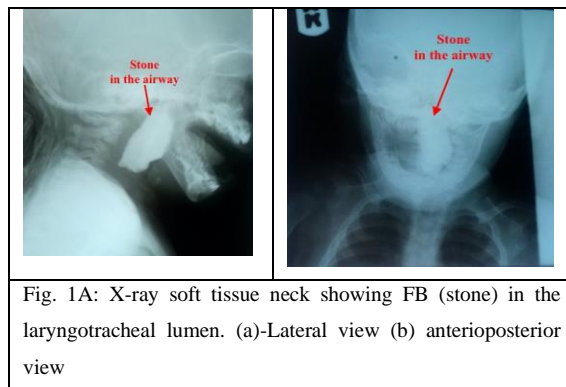
especially where X-ray is not available. Cricothyroidotomy can be done as a quick bed-side procedure by inserting a 16G wide bore cannular through the cricothyroid membrane to establish oxygenation and keep the patient alive while emergency FB removal is being planned.

## CONCLUSION

Foreign body aspiration in children is a public health challenge. Fatal outcome could be averted by prompt referral to specialists, early imaging, and surgical intervention. However, absence of the most skilled manpower or the best instrument should not be allowed to prevent or preclude timely intervention. There is a need to create awareness among parents, care givers and teachers on the importance of safe play environment and adults should always pay close attention to the playing child.

**Table 1: Demographics and clinical analysis of cases**

Case	Age	Symptom	Challenges	Imaging done	Intervention	Instrument used	Outcome
1	9mths	1-Breathlessness. 2. Cyanosis. 3. Body weakness	1. Multiple referral 2. Long Distance 3.Late presentation	X-ray	ENT-Nurse	1-Telley's forceps 2- Tongue depressor	Survived
2	2yrs	Breathlessness	None	X-ray	Anesthetist	1-Macintosh laryngoscope 2-Mc Gies forceps	Survived
3	2yrs	Breathlessness	1.Industrial strike	None	None	None	Died
4	3yrs	Asymptomatic	1.Parent delayed consent. 2.Long distance	None	None	None	Died



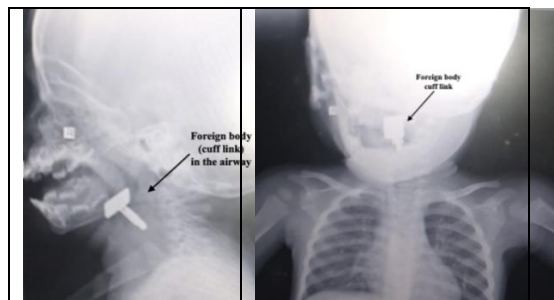


Fig. 2A: X-ray soft tissue neck showing FB (cuff link) in the laryngotracheal lumen. The flat cap of the cuff-link hangs in the supraglottic region while the stem passes in between the vocal cords to lie transglottic (a)-Lateral view (b) anteroposterior view

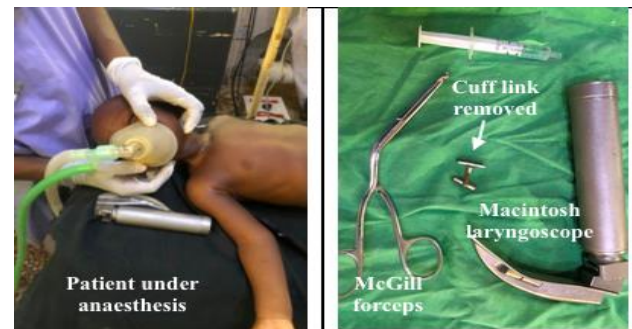


Fig. 2B (a) patient being anaesthetized (b) The foreign body and instruments used for removal

## REFERENCES

1. Hiroaki N, Akiko M, Takashi K, Ryoichi K, Wataru H. Massive haemoptysis caused by a long-standing foreign body in the airway. *Respiratory case reports*. 2020; 8(7):
2. de Blic J., León Cortés A. A Children with an Airway Foreign Body. In: Bertrand P., Sánchez I. (eds) *Pediatric Respiratory Diseases*. Springer, Cham. 2020 [https://doi.org/10.1007/978-3-030-26961-6\\_27](https://doi.org/10.1007/978-3-030-26961-6_27).
3. Ozdemir S, Surmelioglu O, Tarkan O, Tuncer Ulku, Kiroglu M, DagkiranM..The Utility of Endoscope-Assisted Rigid Bronchoscopy in Pediatric Airway Foreign BodyRemovals. *Journal of Craniofacial Surgery* 2020; 31(2): e217-e219. doi: 10.1097/SCS.0000000000005660
4. Bajaj D, Sachdeva D. Foreign body (FB) aspiration requires urgent intervention to avert potential complications and mortality. *J Thorac Dis*. 202; 13(8): 5159–5175. doi: 10.21037/jtd.2020.03.94.
5. Mu L, He P, Sun D. The Causes and Complications of Late Diagnosis of Foreign Body Aspiration in Children: Report of 210 Cases. *Arch Otolaryngol Head Neck* Surg. 1991;117(8):876–879. doi:10.1001/archotol.1991.01870200070010.
6. Ding, G; Wu B, Vinturache A, Cai C, Lu M, Gu H-Tracheobronchial foreign body aspiration in children; A retrospective single-center cross-sectional study. *Medicine*: 2020; 99(22): - 20480. doi: 10.1097/MD.00000000000020480.
7. Montana MA, Feola A, Asmundo A. et al. Risk Management and Recommendations for the Prevention of Fatal Foreign Body Aspiration: Four Cases Aged 1.5 to 3 Years and Mini-Review of the Literature *Int. J. Environ. Res. Public Health* 2020, 17(13), 4700; <https://doi.org/10.3390/ijerph17134700>.
8. Sharma R, Singh R et. al reported an unusual shaped FB that lodged transglottics. A transglottic foreign body in the airway of an infant. *Anaesth Rep*. 2020 Jan-Jun; 8(1): 4–5.
9. Gordon L, Nowik P, Mobibi K S, et al. Diagnosis of foreign body aspiration with ultralow-dose CT using a tine filter: a comparison study. *Emerg Radiol* 2020;27: 399-404. <https://doi.org/10.1007/s10140-020-01764-7>.